

Experimental Research



www.firattipdergisi.com

Important Vascular Anomalies of Face and Neck – A Cadaveric Study with Clinical Implications

Venkata Ramana VOLLALA¹, Sreenivasa Rao BOLLA², Narendra PAMİDİ³

¹ Melaka Manipal Medical College, Anatomy, Manipal,

² Mamatha Medical College, Anatomy, Khammam,

³ Melaka Manipal Medical College, Anatomy, Manipal, INDIA

ABSTRACT

Objectives: The objective of this study was to find out vascular variations in the face and neck region.

Materials and Methods: 75 cadavers of both sexes have been used in the current study. Head and neck dissections of these cadavers were done in the department of anatomy, Kasturba Medical College and Melaka Manipal Medical College, Manipal.

Results: Out of 75 cadavers, we observed five variations in four different cadavers, the findings include; facial vein continuing as external jugular vein after receiving retromandibular and submental veins, low bifurcation of common carotid artery and anomalous branching of external carotid artery, lateral position of external carotid artery, common facial vein draining into external jugular vein, anomalous formation of external jugular vein.

Conclusion: A sound anatomic knowledge of vessels of head and neck is essential. Variations of the superficial venous system and knowledge of variations of the arteries and their branches and their recognition during diagnostic imaging are important for vascular surgical procedures. Since the blood vessels of the head and neck region have immense surgical and diagnostic importance, this study was worthwhile. ©2008, Firat University, Medical Faculty

Key words: Facial vein, External jugular vein, Common carotid artery, External carotid artery.

ÖZET

Yüz ve Boynun Önemli Vasküler Anomalileri-Klinik Önemleriyle Birlikte Bir Kadavra Çalışması

Amaç: Bu çalışmanın amacı yüz ve boynudaki vasküler varyasyonları ortaya çıkarmaktır

Gereç ve Yöntem: Bu çalışmada her iki cinsiyetten 75 kadavra kullanıldı. Bu kadvraların baş ve boyun disseksiyonları Kasturba Medical College ve Melaka Manipal Medical College anatomi bölümleri tarafından yapıldı.

Bulgular: 75 kadvranın tamamı incelendiğinde 4 farklı kadvrada 5 varyasyona rastlandı. Bulgular şunları içeriyordu; V. facialis, v.retromandibularis ve v.submentalis verdikten sonra v.jugularis externa olarak devam ediyordu. Normal pozisyonun daha aşağısında yerleşimli bifurkasyo karotidis ve a.carotis externa nin anormal dallanması. Lateral yerleşimli a.carotis externa. V.jugularis externaya dökülen birleşik facial ven, v.jugularis externanın anormal yapısı.

Sonuç: Baş ve boynun damarların anatomisi iyi bir şekilde bilinmesi gereklidir. Superficial venöz sistem varyasyonları ile arterlerin ve onların dallanmalarının varyasyonlarının bilgileri ve bunların tanınal görüntülenmesi damar cerrahisi işlemleri sırasında önemlidir. Baş ve boyun bölgesinin kan damarları tanı ve cerrahi açısından oldukça önemli olduğundan bu çalışma kayda değerdir. ©2008, Firat Üniversitesi, Tıp Fakültesi

Anahtar kelimeler: V.facialis, v.jugularis externa, a.carotis communis, a.carotis externa.

The facial vein begins as the angular vein at the medial angle of the eye by the union of supra-trochlear and supra-orbital veins. It runs straight downwards and backwards behind the facial artery, and reaches the antero-inferior angle of the masseter where it pierces the deep cervical fascia. In the neck it crosses the submandibular gland and joins with the anterior division of retro-mandibular vein to form the common facial vein, which finally drains into the internal jugular vein. The external jugular vein begins just below the angle of the man-le by union of posterior division of retromandibular vein and posterior auricular vein. It runs obliquely backwards across the sternocleidomastoid appears in the supraclavicular triangle and terminates in the subclavian vein.

Common carotid artery is a branch of brachiocephalic trunk on the right side and arch of aorta on the left side. It normally does not give any other branch in the neck except terminal branches, external and internal carotid arteries. The bifurcation of the common carotid artery takes place in the carotid triangle opposite the disc between third and fourth cervical vertebrae. At the origin the external carotid artery lies antero-medial to the internal carotid artery.

MATERIALS AND METHODS

The study involved the head and neck dissection of 75 cadavers of both sexes. The dissections took place during 1999–2006, in the department of anatomy, Kasturba Medical College and Melaka Manipal Medical College, Manipal. The dissections

were carried out according to the instructions by Cunningham's manual of practical anatomy (1). The bodies were preserved by the injection of a formalin - based preservative (10% formalin) and stored at -4°C .

RESULTS

Our findings include;

Case one: A 50-year-old male cadaver showed facial vein continuing as external jugular vein after receiving retromandibular and submental veins (Figure. 1).

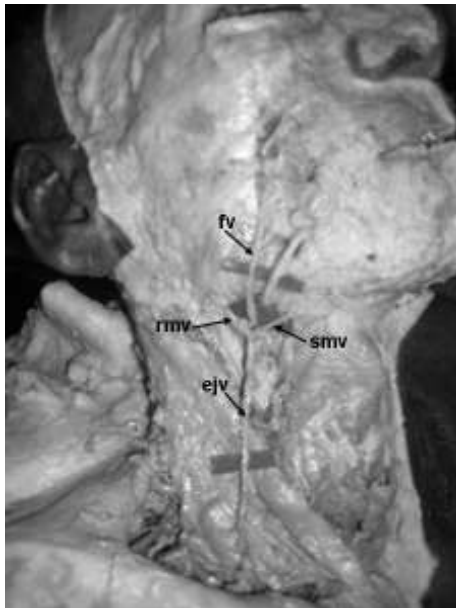


Figure 1. Facial vein continuing as external jugular vein
fv– facial vein, rmv– retromandibular vein, smv– submental vein, ejv– external jugular vein

The formation, course and tributaries of the facial vein were normal in the face, but in the neck it crossed the submandibular gland, received retromandibular and submental veins and continued down as external jugular vein crossing sternocleidomastoid under cover of platysma. It pierced the investing layer of deep cervical fascia about 2.5 cm above the clavicle, appeared in the supraclavicular triangle and terminated in the subclavian vein. The retromandibular vein was formed by union of superficial temporal and maxillary veins in the parotid gland and left the gland by passing through its apex and terminated by opening into facial vein. It did not divide into anterior and posterior divisions. The posterior auricular vein was small and drained into external jugular vein.

The same cadaver showed low bifurcation of common carotid and anomalous branching of external carotid artery (Figure. 2). The common carotid artery bifurcated at the level of sixth cervical vertebra. The external carotid artery gave rise to the superior thyroid artery 1 cm above the bifurcation and linguo-facial trunk 3 cm from the bifurcation at the level of laryngeal prominence, at the same level, it gave rise to the ascending pharyngeal and occipital arteries. Further course and branching pattern of the external carotid artery was normal.

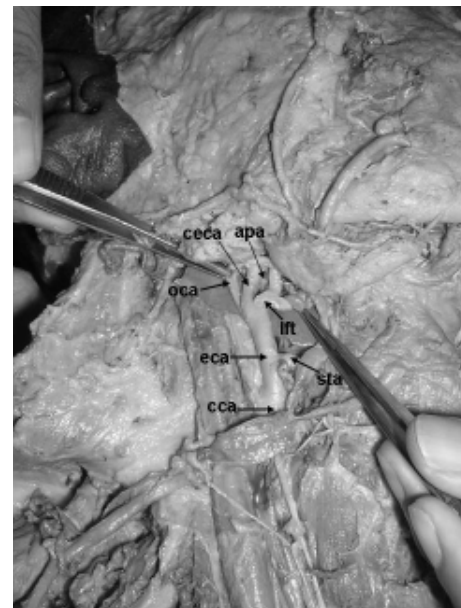


Figure 2. Low bifurcation of common carotid artery and anomalous branching of external carotid artery
cca– common carotid artery, eca- external carotid artery, sta– superior thyroid artery, lft– linguo facial trunk, apa– ascending pharyngeal artery, oca– occipital artery, ceca– continuation of external carotid artery

Case two: A 60-year-old male cadaver presented anomalous termination of common facial vein (Figure. 3).

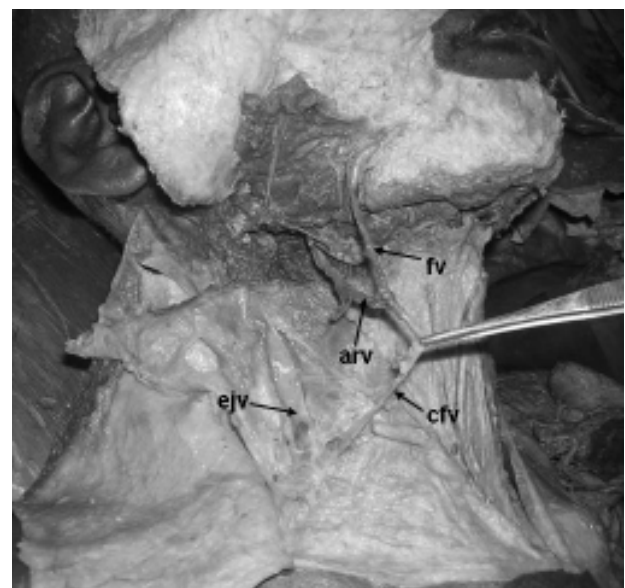

Figure 3. Common facial vein draining into external jugular vein
fv– facial vein, arv– anterior division of retromandibular vein, cfv– common facial vein, ejv– external jugular vein

The common facial vein was formed by union of anterior division of retromandibular vein and facial vein, and then descended down across the sternocleidomastoid to drain into external jugular vein. Case three: A 50-year-old male cadaver showed anomalous formation of external jugular vein (Figure. 4).

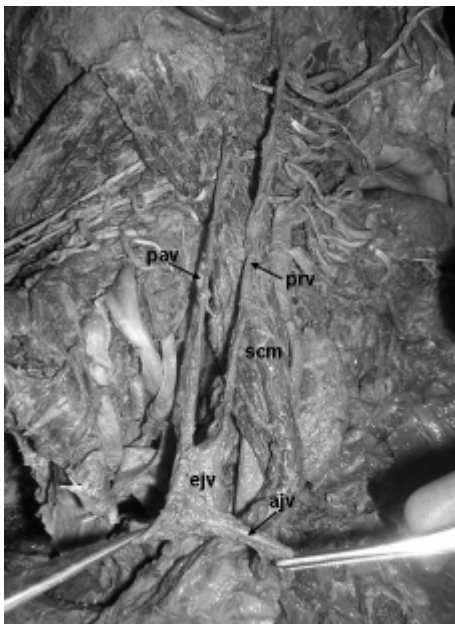


Figure 4. Low formation of external jugular vein

pav- posterior auricular vein, prv- posterior division of retromandibular vein, ejv- external jugular vein, ajv- anterior jugular vein, scm- sternocleidomastoid

The posterior division of retromandibular vein and posterior auricular veins descended obliquely downwards and backwards superficial to the sternocleidomastoid, appeared in the supraclavicular triangle and united to form external jugular vein, which was shorter than normal and received anterior jugular vein before terminating into subclavian vein.

Case four: In the cadaver of a 45-year-old man lateral position of external carotid artery was observed (Figure. 5).

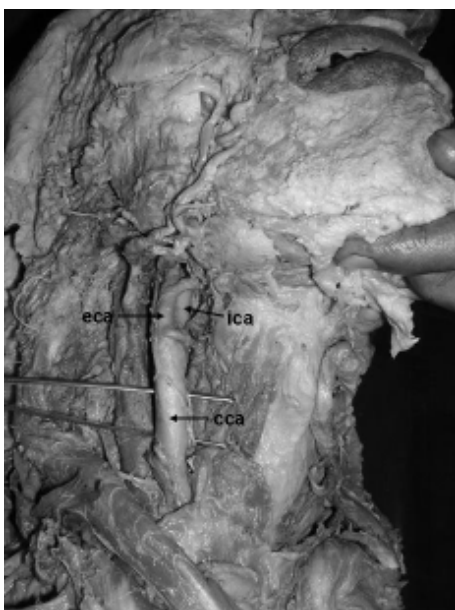


Figure 5. Lateral position of external carotid artery

cca- common carotid artery, eca- external carotid artery, ica- internal carotid artery

The external carotid artery was lateral to the internal carotid artery at the bifurcation of the common carotid artery, ascended up passed deep to the posterior belly of digastric and stylohyoid muscles, and entered the parotid gland. The branching pattern was normal.

All the variations described here were found on the right side of face and neck region. However, on the left side, no such variations were observed. These structures were carefully dissected and photographed.

DISCUSSION

Variations of the external veins of the face and neck – especially the facial and the external jugular veins are not common. There is a report of facial vein draining into superficial temporal vein (2). A study of dissection of 89 cadavers has revealed facial vein draining into external jugular vein in 9% of the specimens (3). In another study of head and neck dissections of 40 cadavers of Indian origin to detect variations of the external jugular vein showed facial vein draining into external jugular vein in 5% of the cases (4). In the current study the facial vein drained into external jugular vein in 1.3% of the specimens. The common facial vein draining into external jugular vein and low formation of external jugular vein has not been reported in the literature. The variations of the superficial veins of the face and neck are of particular importance for different surgical procedures. These veins may be used as patches for carotid endarterectomy and for oral reconstruction (5). In the latter case the facial vein is often needed for microvascular anastomosis. The external jugular vein is increasingly being utilized for cannulation to conduct diagnostic procedures or intravenous therapies. The retromandibular vein is used as a guide to expose the facial nerve branches in superficial parotidectomy and in the open reduction of mandibular condylar fractures. Remembering the varying venous patterns in the head and face region and to avoid an intraoperative ‘trial-and-error’ procedure it is important to evaluate preoperatively the course and branching patterns of the respective vessels, e.g. by means of Doppler ultrasonography (6).

The anomalous drainage of veins is of great significance for vascular surgeons, who are required to command a wide range of anatomical knowledge. In surgery such as carotid endarterectomy, the carotid sheath is opened along the anterior border of the internal jugular vein; the common facial vein, which joins the internal jugular vein just above the carotid bifurcation, provides a useful landmark for the location of the carotid bifurcation. Knowledge of anomalous drainage of the facial vein is therefore important to avoid an inappropriate dissection which may cause severe damage.

The development of reconstructive microsurgery has paralleled the discovery of the true nature of the circulation of the skin. The robust circulation of the head and neck region permits the design of many cutaneous flaps such as the platysma flap or a sternocleidomastoid myocutaneous flap. Venous anomalies and variations of the superficial venous system are therefore important to know, to avoid damage to fascia and ensure survival of the flap (7).

Knowledge of variations in the external jugular vein is of great importance as this is an important drainage site for shunt procedures involving the lateral ventricle in hydrocephalus surgery. Various other applications e.g., percutaneous central vein cannulation, maxillo-facial surgery, biocompatibility studies for synthetic materials for prostheses, total parental

nutrition in critically ill patients, invasive monitoring, etc. all make use of this vein. A sound anatomic knowledge of the formation, course and tributaries of the external jugular vein is essential to the success of surgical procedures in this region.

There are reports of lateral position of external carotid artery (8–10). In a study lateral position of the external carotid artery was seen in 17 cases (4.3%), of which 13 cases were on the right side and 4 cases on the left (8). It is necessary to know the lateral position of the external carotid artery for the correct diagnosis by intravenous digital subtraction angiography (IVDSA) and doppler scanning. During bleeding from terminal branches of external carotid artery occasionally it is necessary to consider ligation of the artery. It is very important to ensure that the artery being ligated is indeed the external carotid artery

rather than internal carotid as ligation of latter causes a high risk of hemiparesis. An unusual case of peripheral hypoglossal nerve palsy, caused by lateral position of the external carotid artery and an abnormally high carotid bifurcation has been reported (11). Improvement followed ligation and cutting of the external carotid artery at its origin. The present variation may be of particular interest to surgeons and anatomists.

Knowledge of variations of the external carotid artery and its branches and their recognition during diagnostic imaging are also important for vascular surgical procedures in the region, such as carotid endoplasty for the treatment of carotid stenosis (12,13) or extracranial-intracranial arterial bypass for the treatment of patients with occlusive cerebrovascular disease, skull-base tumors or aneurysms (14).

REFERENCES

- Romanes GJ. Cunningham's Manual of Practical Anatomy. 15th ed, Volume three, Head and Neck and Brain. Oxford University Press. 1996; 22: 35 - 36, 39-40.
- Peuker ET, Fischer G and Filler TJ. Facial vein terminating in the superficial temporal vein: a case report. *J. Anat* 2001; 198: 509-510.
- Gupta V, Tuli A, Choudhry R, Agarwal S, Mangal A. Facial vein draining into external jugular vein in humans: its variations, phylogenetic retention and clinical relevance. *Surg Radiol Anat* 2003; 25: 36-41.
- Choudhry R, Tuli A, and Choudhry S. Facial vein terminating in the external jugular vein An embryologic interpretation. *Surg Radiol Anat* 1997; 19: 73-77.
- Sabharwal P, Mukherjee D. Autogenous common facial vein or external jugular vein patch for carotid endarterectomy. *Cardiovascular Surgery* 1998; 6: 594-597.
- Nagase T, Kobayashi S, Sekiya S, Ohmori K. Anatomic evaluation of the facial artery and vein using color Doppler ultrasonography. *Annals of Plastic Surgery* 1997; 39: 64-67.
- Roger KK, Joseph U. Fascia flaps in the head and neck. In: *Fasciocutaneous flaps*. Blackwell, London. 1992; 27-29.
- Bussaka H, Sato N, Oguni T, Korogi M, Yamashita Y, Takahashi M. Lateral position of ECA. *Rhinsho hoshasen* 1990; 35: 1061-1063.
- Handa J, Matsuda M, Handa H. Lateral position of the external carotid artery. Report of a case. *Radiology* 1972; 102: 361-362.
- Braeuer NR, Mallamo JT, Lynch RD. Anomalous lateral and inferior position of the external carotid artery: case report. *J Can Assoc Radiol* 1975; 26: 210-211.
- Ueda S, Kohyama Y, Takase K. Peripheral hypoglossal nerve palsy caused by lateral position of the external carotid artery and an abnormally high position of bifurcation of the external and internal carotid arteries—a case report. *Stroke* 1984; 15: 736-739.
- Brown MM, Butler P, Gibbs J, Swash M, Waterston J. Feasibility of percutaneous transluminal angioplasty for carotid artery stenosis. *J Neurol Neurosurg Psychiat* 1990; 53: 238 – 243.
- Dillon EH, van Leeuwen MS, Fernandez MA, Eikelboom BC, Mali WPTM. CT Angiography application to the evaluation of carotid artery stenosis. *Radiology* 1993; 189: 211-219.
- Gratzl O, Schmiedek P, Spetzler R, Steinhoff H, Marguth F. Clinical experience with extra-intracranial arterial anastomosis in 65 cases. *J Neurosurg* 1976; 44: 313-324.

Kabul Tarihi: 13.12.2007