

## Symptomatic Chiari Malformation with Syringomyelia after Cervical Trauma: Case Report

Serdar KABATAŞ<sup>2</sup>, Tufan CANSEVER<sup>a2</sup>, Cem YILMAZ<sup>1</sup>, Aykan AKAR<sup>1</sup>, Erdiñ ÇİVELEK<sup>2</sup>,  
Nur ALTINÖRS<sup>1</sup>

<sup>1</sup>Başkent Üniversitesi Tıp Fakültesi, Beyin ve Sinir Cerrahisi, ANKARA, Türkiye

<sup>2</sup>Başkent Üniversitesi Tıp Fakültesi, Beyin ve Sinir Cerrahisi, İSTANBUL, Türkiye

### ABSTRACT

Chiari malformation type-I (CM-I) is a congenital disorder characterized by downward displacement of the cerebellar tonsils thru the foramen magnum, with/ without syringomyelia. The patients can be asymptomatic until an aggravation condition like cervical trauma occurs. We present a 54 years old male patient suffering from neck pain after traffic accident. He had mild motor weakness in upper extremities. His neuroradiological examinations revealed C6-7 facet and C7 lamina fractures; syringomyelia descending from C1 to T3 and a CM-I. In early post-traumatic follow-up period, his weakness was progressed, foramen magnum decompression and posterior cervical stabilization was performed. His motor weakness recovered and follow-up magnetic resonance imaging (MRI) examination showed an evident regression of syrinx diameter. It should be kept in mind that previously asymptomatic CM-I patients can become symptomatic after cervical trauma.

**Key words:** Asymptomatic, cervical, trauma, Chiari Malformation type-I

### ÖZET

#### Servikal Travma Sonrası Belirti Veren Chiari Malformasyonu: Olgu Sunumu

Chiari Malformasyonu Tip I (CM-I), serebellar tonsillerin foramen magnumdan fıtıklaşması ve genelde sirengomyelinin eşlik ettiği konjenital hastalıktır. Servikal travma gibi tetikleyen bir durum olmadığı sürece belirti vermeyebilir. Trafik kazası sonrası boyun ağrısından şikayet eden bir 54 yaşında erkek hasta sunuldu. Üst ekstremitelerinde hafif parezisi vardı. Nöroradyolojik incelemelerinde C6-7 faset ve C7 lamina fraktürü; C1 seviyesinden T3 seviyesine kadar uzanan sirengomyelik kavite ve CM-I tespit edildi. Travma sonrası erken dönemde parezisi artan hastaya foramen magnum dekompresyonu ve posterior servikal stabilizasyon uygulandı. Hastanın parezisinin gerilediği ve izlem manyetik rezonans incelemelerinde sirengomiyelinin küçülme olduğu tespit edildi. Belirti vermeyen CM-I hastalarının travma sonrası belirti verebileceği akılda tutulmalıdır.

**Anahtar Sözcükler:** Asemptomatik, servikal, travma, Chiari Malformasyonu tip-I

Chiari malformation type-I (CM-I) is the displacement of the cerebellar tonsils inferior to the plane of the foramen magnum that may be seen as a congenital disorder of the mesoderm because of a small posterior fossa (6). A second group of patients may acquire CM-I due to lumboperitoneal shunts, birth trauma, tumors or meningeal reactions at the foramen magnum (2). Additionally, syringomyelia has been noted in 75-85% of the population with CM-I (4). It had been reported that CM-I is symptomatic when the herniation is more than 12 mm. The patients with herniation of 5-10 mm, 30% are symptomatic and of those that are below 5 mm is usually asymptomatic (1). We report a case with asymptomatic non-communicating syringomyelia associated with a CM-I exacerbated within hours of a traumatic cervical injury.

### CASE REPORT

A 54 year old male patient was admitted to our department due to traffic accident. His major complaint was neck pain.

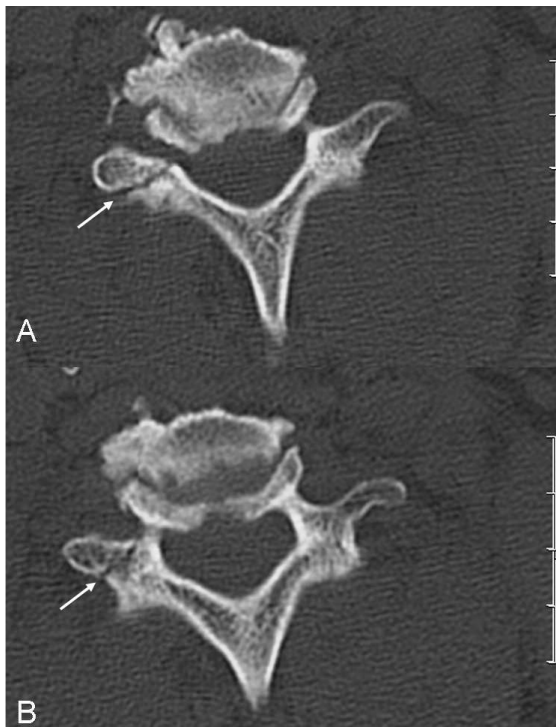His neurological examination revealed a minor motor deficit in the right biceps and triceps muscles (4 out of 5). Cervical CT showed C6-7 facet and C7 lamina fractures (Figure 1 A, B). In early post-traumatic follow-up period (~3 hours), his weakness was progressed in two days follow-up (2 out of 5). Cervical magnetic resonance imaging (MRI) was suggested a syringomyelia descending from C1 to T3 level with CM-I at 14 mm tonsillary herniation (Figure 2 A). Furthermore, the patient recounted any history which might be suggestive of CM-I. Thus, the patient underwent surgery and a decompression of the craniovertebral junction was performed. The C7 lamina and the facet fractures were treated by terms of C6/C7 total laminectomy and posterior cervical stabilization. The postoperative period was uneventful and motor deficit of the patient was improved. He was discharged and postoperative cervical MRI after three months showed a significant decrease in the diameter of the syringomyelia (Figure 2 B).

<sup>a</sup> Corresponding Adress: Dr. Tufan CANSEVER, Başkent Üniversitesi Tıp Fakültesi, Beyin ve Sinir Cerrahisi, ANKARA, Türkiye

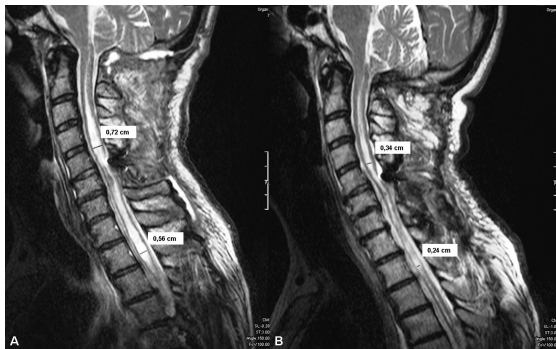
\*1st Middle East Neurosurgical Symposia

Tel: +90 532 6157789

e-mail: drtufan@gmail.com



**Figure 1. A-B:** Cervical axial CT showed right C6-7 facet and C7 lamina fractures.



**Figure 2.** Sagittal T2-weighted cervical MRIs revealed a syringomyelia descending from C1 to T3 level with CM-I at 14 mm tonsillar herniation, 0.6 mm in diameter (A) and a significant decrease in the diameter of the syringomyelia at postoperative third month, 0.34 mm in C5 and 0.24 mm in T2 level, respectively (B).

## REFERENCES

- Barry A, Patten BM, Stewart BH. Possible factors in the development of the Arnold-Chiari malformation. *J Neurosurg* 1957; 14: 285-301.
- Chumas PD, Armstrong DC, Drake JM, et al. Tonsillar herniation: the rule rather than the exception after lumboperitoneal shunting in the pediatric population. *J Neurosurg* 1993; 78: 568-573.
- Edgar R, Quail P. Progressive post-traumatic cystic and non-cystic myelopathy. *Br J Neurosurg* 1994; 8: 7-22.
- Klekamp J, Batzdorf U, Samii M, et al. The surgical treatment of Chiari I malformation. *Acta Neurochir (Wien)* 1996; 138: 788-801.
- Koyanagi I, Houkin K. Pathogenesis of syringomyelia associated with Chiari type I malformation: review of evidences and proposal of a new hypothesis. *Neurosurg Rev.* 2010; 33: 271-284.
- Milhorat TH, Chou MW, Trinidad EM, et al. Chiari I malformation redefined: clinical and radiographic findings for 364 symptomatic patients. *Neurosurgery* 1999; 44: 1005-1017.
- Milhorat TH, Capocelli AL Jr, Anzil AP, et al. Milhorat RH. Pathological basis of spinal cord cavitation in syringomyelia: analysis of 105 autopsy cases. *J Neurosurg* 1995; 82: 802-812.
- Milhorat TH. Classification of syringomyelia. *Neurosurg Focus* 2000; 8: E1.
- Milhorat TH, Johnson RW, Milhorat RH, et al. Clinicopathological correlations in syringomyelia using axial magnetic resonance imaging. *Neurosurgery* 1995; 37: 206-213.
- Oldfield EH, Muraszko K, Shawker TH, et al. Pathophysiology of syringomyelia associated with Chiari I malformation of the cerebellar tonsils. Implications for diagnosis and treatment. *J Neurosurg* 1994; 80: 3-15.

## DISCUSSION

Syringomyelia is a heterogeneous collection of conditions characterized by the presence of abnormal fluid filled cavities (syringes) within the spinal cord. Milhorat et al. (5-9) have divided syringes into five according to pathological and MRI findings. These are communicating central canal, non-communicating central canal, and non-communicating extracanalicular syringes, atrophic cavitations, and neoplastic cavities (7). With respect to this classification, the current case had a non-communicating central canal syrinx. Additionally, it had been reported that CM-I is symptomatic when the herniation is more than 12 mm (1). Although our case was asymptomatic in the initial period, thereafter it was determined that the tonsillary herniation was 14 mm from the craniocervical junction.

Regarding post-traumatic syringes are usually juxtaposed to the injury site and extend rostral in 81%, caudal in 4%, and in both directions in 15% of cases (10). Up to 17% of post-traumatic syringes extend more than ten levels (3, 7). In our case, it was extended to both directions and ten levels (C1 to T3). The innovative theory proposed by Oldfield et al. (10) suggested that the downward tonsillar displacement hinders the rapid bi-directional cerebrospinal fluid (CSF) passage across the foramen magnum, which normally occurs during each cardiac cycle in response to the pulsatile expansion and contraction of the brain. The partially isolated spinal subarachnoid spaces are therefore poorly compliant to the abrupt CSF volume changes induced by the downward tonsillar thrust that occurs at each systole. This generates increased pulsatile pressure waves that may force CSF to penetrate the spinal cord, whereby CSF acts on its surface and eventually causes a syrinx to form.

While in most of the CM-I patients, symptoms may occur spontaneously, 24% of the patients have a cervical trauma history as in our case (6). Although the exact pathophysiology is uncertain, it is widely believed that after cervical trauma with tonsil herniation, the resistance against CSF and the subarachnoid space is increased causing expansion in the subarachnoid space and advancement of the syringohydromyelic cavity (6).

Considering the patients with cervical trauma and neurological deficit, it should be kept in mind that previously asymptomatic CM-I patients can become symptomatic after cervical trauma.

*Kabul Tarihi: 23.08.2010*