

Case Report



An Unusual Mass of the Neck: Primary Hydatid Cyst

Salih BAKIR^{a1}, Ramazan GUN¹, Ugur FIRAT², Ediz YORGANCILAR¹, Guven TEKBAS³, Ismail TOPCU¹

¹Dicle University Faculty of Medicine, Department of Ear Nose and Throat, Diyarbakir, Turkey

²Dicle University Faculty of Medicine, Department of Pathology, Diyarbakir, Turkey

³Dicle University Faculty of Medicine, Department of Radiology, Diyarbakir, Turkey

ABSTRACT

Hydatid disease is a common parasitic infestation caused by the parasite *Echinococcus granulosus*. It is a serious health problem most frequently encountered in rural areas where domestic livestock-raising is common. Complete surgical excision is the gold standard treatment for hydatid cyst. Postoperative medical treatment with antihelminthic drugs (benzimidazole derivatives) are frequently combined with surgical treatment to prevent recurrence of disease and high-risk contamination. Although hydatid cysts usually involve in liver and lungs, less frequently may occur in any area of the body. A hydatid cyst occurrence in the head and neck area is extremely rare. So this disease does not usually come to mind. Therefore in this case, we wish to draw attention to possibility of the hydatid disease in the neck. For this reason, we present an unusual case of primary hydatid cyst located in the neck region in a 50-year-old male patient.

Keywords: *Echinococcosis, Neck, Helminths.*

ÖZET

Nadir Bir Boyun Kitlesi: Primer Hidatik Kist

Hidatik kist hastalığı, *Echinococcus granulosus* adlı tenyanın larvalarının neden olduğu parazitik bir enfestasyondur. Büyük ve küçükbaş hayvan yetiştiriciliğinin yaygın olduğu kırsal kesimlerde ve köpek besleme alışkanlığının bulunduğu insan topluluklarında sık görülür. Hidatik kistin tedavisinde cerrahi "altın standart" olarak kabul edilmektedir. Benzimidazol türevleri cerrahi yapılamayacak olgularda ya da cerrahi sonrası rekürrensleri önlemek için kullanılır. Kist hidatik genellikle karaciğer ve akciğerde görülmekle beraber, vücudun herhangi bir bölgesinde oluşabilir. Baş ve boyun bölgesinde kist hidatik oluşumu son derece nadirdir. Bu yüzden boyunda kitle ile gelen hastada bu hastalık genellikle ayırıcı tanıda akla gelmez. Bu nedenle bu olgu sunumunda, 50 yaşındaki bir erkek hastanın primer kist hidatik tanısı almış boyun bölgesindeki nadir kistik kitleyi sunarak, boyunda hidatik kist hastalığı olasılığına dikkat çekmek istedik.

Anahtar Kelimeler: *Ekinokokkozis, Boyun, Helminthler.*

Hydatic cyst disease (echinococcosis) is a common parasitic infestation caused by the larval form of the tapeworm *taenia echinococcus* (1). It is a serious health problem most frequently encountered in rural areas of countries where domestic livestock-raising is common (2, 3). It affects both animals and humans. Animals are main factors in the spread of hydatids (3). Dog is the definitive host. Some intermediate hosts are sheep, goat, cattle, camel, pig, horses and rarely humans (3). Humans can be infected accidentally through oral ingestion of tapeworm eggs with contaminated water, food, and green vegetables or direct contact with host (1, 3).

Although it is most common in the liver and lungs, it can be located in almost every part of the body and it can involve multiple organs. Head and neck involvement of hydatid cyst is extremely rare even in geographical areas in which echinococcal infestation is endemic. Only a few cases of hydatid cyst located in

neck have been reported in literature (4, 5). So this disease does not usually come to mind. Therefore in this case, we wish to draw attention to the possibility of the of hydatid disease in the case of a cystic mass of the neck region. For this reason, we present a case of a big hydatid cyst located in the posterior side of the neck in this report.

CASE REPORT

A 50-year-old man, who was a farmer from a rural area, admitted to our clinic with a 1-year history of a painless, slowly progressive growing swelling located in the right posterior region of his neck (Figure 1). No other accompanying complaint was present. On physical examination, this smooth 9x6 cm fluctuating mass was painless, and with no local inflammatory response. On blood examination the total leukocyte count was 11400 cells/L and 7.96 % eosinophils. Neck ultrasonography (USG) showed a unilocular, anechoic

^a Corresponding Adress: Dr. Salih BAKIR, Dicle University Faculty of Medicine, Department of Ear Nose and Throat, Diyarbakir, Turkey
e-mail: drsalihbakir@hotmail.com

cystic mass with thickened walls, and 85 x 55 mm dimensions. Computed tomography (CT) of the neck showed a simple cystic mass with dimensions of 6x4.5x9 cm in the right side of the posterior cervical region (Figure 2). Therefore, we performed fine-needle aspiration biopsy (FNAB) of the mass. When FNAB was performed, a crystal-clear liquid was drained. Elevated antibody (Echinococcus granulosus-IgG positive: 1/100) was detected in cytology of the drained fluid aspiration of the cyst. Therefore the diagnosis of hydatid cyst was strongly suspected.

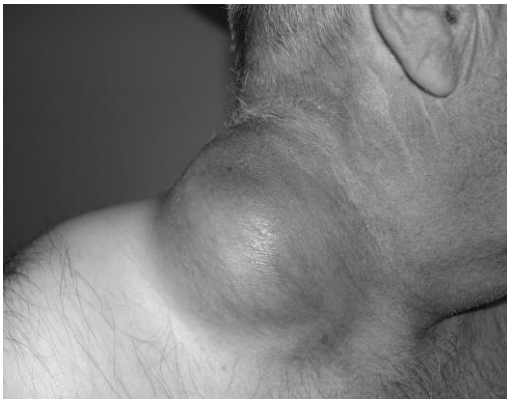

Figure 1. Preoperative view of mass.

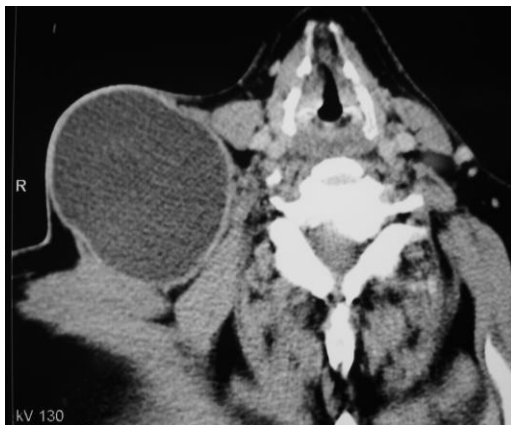

Figure 2. Axial computed tomography (CT) scan shows a welldefined, rounded, cystic mass.

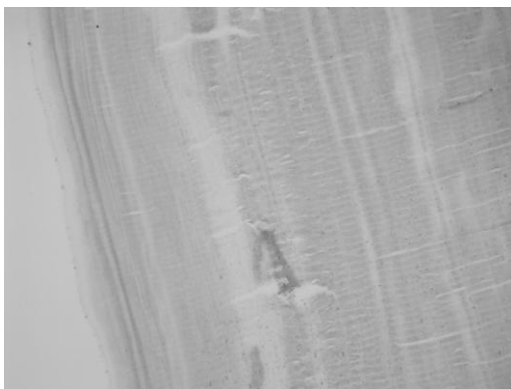


Figure 3. Inner germinal layer of the cyst (H&E stain, X100).

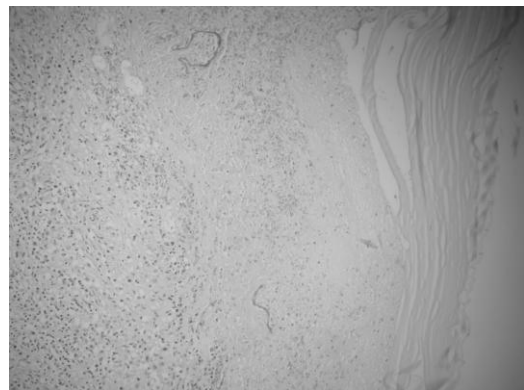


Figure 4. The cyst wall shows a rim of necrosis and granulomatous reaction containing neutrophils and prominent eosinophils (H&E stain, X100).

Total excision of the mass was undertaken under general anesthesia. The neck was explored and cystic mass was completely dissected from the surrounding structures with protecting the integrity of its capsule. Then the operative field was irrigated with hypertonic saline (20%) solution. On gross examination, the cyst measured 9 cm in diameter, and not any daughter cysts were identified in the fluid. Preoperative diagnosis of hydatid disease was confirmed histopathologically after surgical removal of the cystic mass. On histomorphologic examination revealed a cyst wall showing an outer fibrous laminar layer and an inner germinal layer (Figure 3). Sections from the biopsy of the cyst showed that the cyst wall was surrounded by a granulomatous inflammation containing neutrophils and prominent eosinophils, and a peripheral rim of necrosis (Figure 4). Some areas of the cyst showed focal calcification signifying the cyst was dead probably because of the injection of hypertonic saline (20%) solution.

To exclude the possibility of invasion to the visceral organs for other hydatid cysts, the patient was subjected to CT scan and USG did not reveal any hepatic or pulmonary or extracervical site involvement. Postoperatively, the patient began receiving albendazol 400 mg twice daily, for 3 months. At the 3-month follow-up, he has been disease free.

DISCUSSION

Human hydatid cysts are an endemic disease in Turkey, and the annual incidence of hydatid disease is 4.7 cases per 100,000 inhabitants (6). Hydatid cysts most frequently localize to the liver and lungs, but less frequently may occur in many parts of the body. The liver has been involved in 55%, and the 45% other locations are lung (40%), spleen (1.8%), kidney (1.4%), bone (0.1%) and other remaining sites (1.7%) (7). Considering these results, the possibility of hydatid cyst in the neck is very low. Therefore, it is difficult to

remember hydatid cyst disease in a patient with swelling in the neck. Besides rarity, most hydatid cysts are asymptomatic and characteristically slow-growing. Due to symptoms and the clinical findings are not specific, this kind of patients occupation, geographic region, medical history and family history should alert the physician in diagnosing head and neck cyst hydatid disease (8, 9).

Laboratory tests except eosinophilia are not helpful (3). Eosinophilia is seen in 25% of cases (5). In order to confirm the diagnosis, serological tests, including immune hemagglutination, complement fixation, immunoelectrophoresis, skin tests (Casoni intradermal test), enzyme-linked immunosorbent assay (ELISA) and western blot serology are usually used to detect antibodies in serum of patients especially in abdominal disease (3). But in extrahepatic involvement, they have low diagnostic sensitivity and specificity (3). Therefore, positive serological results do not confirm the diagnosis of hydatid cyst, and on the other hand negative results do not exclude it.

Radiologic methods are more valuable diagnostic tools than serologic tests. The diagnosis of hydatid disease is made mainly with the help of imaging methods. Even in the presence of negative serologic results, a characteristic radiologic demonstration should still suggest the diagnosis of echinococcosis (10). USG and CT greatly facilitate the diagnosis of hydatid cyst of the neck. Especially CT is a successful method for the early and accurate diagnosis and establishing the appropriate diagnosis (10).

Fine-needle aspiration biopsy is controversial in hydatid disease. FNAB is inconclusive unless one submits it for microscopic examination with a high suspicion index. If adequate measures are taken, FNAB may be useful in the evaluation of suspected hydatid disease (9). Some authors reported that no complications were encountered (9). But generally, it has not been advised because of the potential to precipitate allergic reactions or acute anaphylaxis or to spread daughter cysts (8). But we performed FNAB of the mass because of radiologic findings are not demonstrative and not suspect from cyst hydatid disease. Fortunately, any complication was not observed in our case. An open biopsy should be avoided definitely (1).

Although imaging techniques are reported to be highly sensitive in hydatid cysts of the head and neck, sometimes diagnosis will be missed in some cases (5). The definite diagnosis of hydatid disease could only be made in histopathologic specimens after removal of cyst (5). Echinococcosis usually forms one, fluid-filled unilocular cyst (9). It consists of an inner germinal layer of cells supported by a characteristic acidophilic-staining, acellular, laminated membrane of variable thickness. Each cyst is surrounded by a host-produced

layer of granulomatous adventitial reaction tissue, which is a thick fibrous tissue (9).

Hydatid cyst of the neck should be considered in the differential diagnosis of any tumor-like growing mass. Other congenital and acquired cystic lesions of neck should be differentiated from this rare entity. Congenital cysts include dermoid and epidermoid cysts, first branchial cleft cysts, and cystic hygromas (2).

The gold standard treatment for hydatid cyst is complete surgical excision (4, 5, 7, 8). During surgery, to avoid spilling the contents of cyst is very important (9). Hydatid cyst fluid is highly allergenic. If the cystic contents spill out in the neck, parasit may transform into multiple hydatosis and it can result in fever, urticaria, anaphylactic shock or reinfection (5). Therefore, to avoid further complications, injection of hypertonic saline solutions (20%) into the cyst prior to removal, could be helpful to prevent possible acute allergic reactions and formations of secondary cysts caused by the spillage of the contents (1).

Postoperative medical treatment with antihelminthic drugs are frequently combined with surgical treatment to prevent recurrence of disease and high-risk contamination. The suggested optimal period for adjuvant therapy after surgery with benzimidazole derivatives (albendazole, mebendazole) is 3-12 months at a daily dose of 10 mg/kg of body weight (11). Because of albendazole has better gastrointestinal absorption and higher plasma levels, it is preferred over mebendazole (11). Although there was not any other organ involvement in our case, we treated the patient with albendazole (400 mg twice daily) for 3 months postoperatively. Medical treatment may also be preferred if surgery is not performed because of any reason for the following: patients with multiple organ involvement, patients with a cyst in unattainable location, patients with a poor general condition that makes surgery an unacceptable risk (7-9). But, the results are unpredictable. Blood count and transaminases must be checked routinely after the medication (2, 3). Because these drugs may have adverse effects on liver and hematological systems (3).

Hydatid cyst involvement may occur in isolated regions without presence of hepatic or pulmonary lesions. When the patient with hydatid disease of unusual localization is diagnosed, the other more common sites such as liver and lungs should be searched (8). In our case, no liver and lung involvement were detected by radiologic evaluation.

In conclusion, hydatid cyst rarely appears in the neck but it should be considered in the differential diagnosis of lesions causing slow-growing cystic swelling of the neck.

REFERENCES

1. Celik A, Turanlı M, Kutun S, et al. Unusual location of hydatid cyst: soft tissue mass in the neck. *Eur Arch Otorhinolaryngol* 2006; 263: 1147-1150.
2. Darabi M, Varedi P, Mohebi AR, et al. Hydatid cyst of the parotid gland. *Oral Maxillofac Surg* 2009; 13: 33-35.
3. Çelik C, Şaşmaz MF, Uçan H. Spinal Hydatid Cyst: Review. *Türkiye Klinikleri J Med Sci* 2010; 30: 1073-1077.
4. Eroglu A, Atabekoglu S, Kocaoglu H. Primary hydatid cyst of the neck. *Eur Arch Otorhinolaryngol* 1999; 256: 202-204.
5. Katılmış H, Ozturkcan S, Ozdemir I, Adadan Güvenç I, Ozturan S. Primary hydatid cyst of the neck. *Am J Otolaryngol* 2007; 28: 205-207.
6. Kilic D, Kaya I, Kamas A. Health Statistics. Turkey: Republic of Turkey Ministry of Health, Research Planning Coordination Council 2002; 54.
7. Dziri C, Haouet K, Fingerhut A, Zaouche A. Management of cystic echinococcosis complications and dissemination: where is the evidence? *World J Surg* 2009; 33: 1266-1273.
8. Baglam T, Karatas E, Durucu C, et al. Primary hydatid cyst of the infratemporal fossa. *J Craniofac Surg* 2009; 20: 1200-1201.
9. Tekin M, Osma U, Yaldiz M, Topcu I. Preauricular hydatid cyst: an unusual location for echinococcosis. *Eur Arch Otorhinolaryngol* 2004; 261: 87-89.
10. Adaletli I, Yigiter R, Selcuk D, Siricki A, Senyuz OF. Primary Hydatid Cyst of the Head and Neck Diagnosed with Ultrasound and Computed Tomography: A Report of Two Cases. *South Med J* 2005; 98: 830-832.
11. Sartbeyoğlu K, Erenler Kılıç İ. The perioperative use of scolical agents and medical treatment in hydatid disease. *Türkiye Klinikleri Surg Med Sci* 2006; 2: 45-48.

Gönderilme Tarihi: 06.03.2011