

Case Report



Paranasal Sinus Mucoceles: Report of Cases in Four Different Localisations, Two of Which are Uncommon

Ayşe Oznur AKIDİL, Mahmut Sinan YILMAZ^a, Mehmet GUVEN

Sakarya Training and Research Hospital, Ear, Nose and Throat Clinic, Sakarya, Turkey

ABSTRACT

Paranasal sinus mucoceles are relatively common, benign, slow growing cystic lesions filled with mucous or mucopurulent material that overflow the sinus. They are locally expansile and can cause bone destruction. These lesions are thought to be secondary to an obstruction of the sinus ostium caused by an inflammation, trauma, fibrosis, or previous surgery. They are frequently located in the frontal sinus and ethmoid sinuses, and are seen rarely in the maxillary and sphenoid sinuses. Middle turbinate and septum mucoceles are seen very rarely. In this report we present a literature review and five cases of paranasal sinus mucocele in four different localisations, two of which are uncommon.

Key words: *Paranasal sinuses, Mucocele, Surgical treatment, Endoscopic sinus surgery*

ÖZET

Paranasal Sinüs Mukoselleri : İki Nadir Dört Farklı Lokalizasyonda Vaka Sunumu

Paranasal sinüs mukoselleri göreceli olarak yaygın görülen, sinüsü dolduran ve içi mukus veya mukopürülan materyal ile dolu, sinüsü dolduran, lokal olarak genişleyen ve kemik harabiyetine sebep olabilen, benign, yavaş büyüyen kistik lezyonlardır. Bu lezyonların bir inflamasyon, travma, fibrozis veya geçirilmiş cerrahiye bağlı olarak ortaya çıkan sinüs ostiumunun tıkanması sonucu olduğu düşünülmektedir. En sık yerleşim yeri frontal sinüs ve etmoid sinüslerdir. Maksiller ve sfenoid sinüslerde nadiren görülürler. Orta konka ve septum mukoselleri nadiren görülmektedir. Bu yazıda biz, iki tanesi alışılmadık olmak üzere dört ayrı lokalizasyonda yerleşmiş beş paranasal sinüs mukoseli vakasını sunuyor ve literatürü gözden geçiriyoruz.

Anahtar Sözcükler: *Paranasal sinüsler, Mukosel, Cerrahi tedavi, Endoskopik sinüs cerrahisi*

Mucoceles are relatively common, benign, slow growing cystic lesions of the paranasal sinuses. It generally takes many years for them to become symptomatic. These lesions are thought to be secondary to an obstruction of the sinus ostium caused by an inflammation, trauma, fibrosis, or previous surgery. They are lined with respiratory mucosa that produces mucous in a physiologic manner (1). Symptoms of the paranasal sinus mucoceles may vary depending on the size and location of the mucocele.

Frontal sinus and ethmoid sinuses are the most frequent locations. They are seen rarely in the maxillary and sphenoid sinuses. However, some reports in the literature present the findings of surgically proven mucoceles with uncommon locations such as pterygo-maxillary space, orbital floor and os nasale (2), middle turbinate (3) and nasal septum (4). This report presents five cases of mucoceles that occurred in four different locations of the paranasal sinuses (Table 1) and a literature review.

CASE REPORT

Case 1

A 33 years old male admitted to our outpatient c-

linic with left sided facial and periorbital pain. He had no history of trauma, surgery or allergy. The physical examination was normal. The computed tomography (CT) in coronal view revealed a cystic mass near the left maxillary sinus ostium, filling the ethmoid sinuses causing erosion in lamina papyracea (Figure 1a). The patient underwent endoscopic sinus surgery under general anesthesia. The mucoid material was drained and the cyst marsupialized. The diagnosis of a mucocele was confirmed histologically. The patient uneventfully recovered from surgery and continues to do well 2 years after the surgery (Figure 1b).

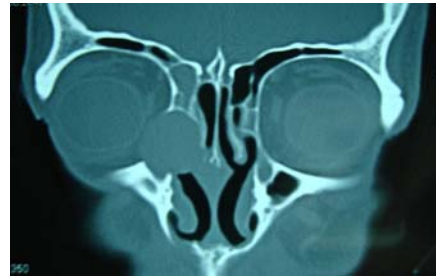


Figure 1a. The cystic mass near left maxillary sinus ostium, filling the ethmoid sinuses causing erosion in lamina papyracea.

^a Corresponding Adress: Dr. Mahmut Sinan YILMAZ, Sakarya Training and Research Hospital, Ear, Nose and Throat, Sakarya, Turkey
e-mail: yilmazms@gmail.com

*Bu çalışma 33rd Turkish Congress of Otorhinolaryngology Head and Neck Surgery, Antalya – Turkey 26-30 October 2011’de sunulmuştur.

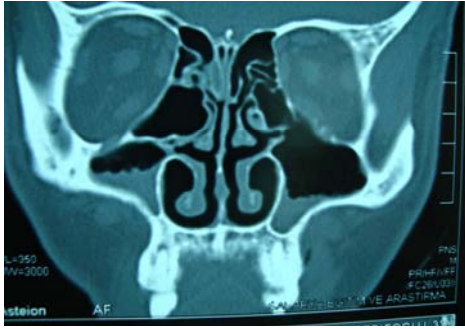

Figure 1b. Control CT taken 2 years after the surgery reveals no mucocele.

Case 2

A 50 years old male was referred to our outpatient clinic from an ophthalmology clinic. He was suffering from epiphora and lateralization in the right eye. The nasal endoscopic examination found a smooth surfaced mass in the projection of middle turbinate. CT showed a lobulated mass with a diameter of 35x33 mm located in the right orbita medial wall, approximately filling the right nasal cavity, destructing the bone structures, compressing the medial rectus muscle, and displacing the orbita anteriorly and laterally (Figure 2). The patient underwent endoscopic sinus surgery. The lesion was excised, the cyst contents and wall were removed successfully and the lamina papirecea was found defective. The histological examination of the material was compatible with mucocele. Postoperatively, the patient's symptoms diminished quickly. He was symptom-free over the next six months and there was no evidence of recurrence.

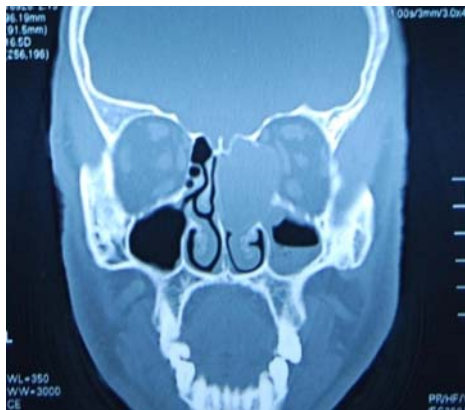

Figure 2. The lobulated mass approximately filled the right nasal cavity, destroying the bone structures and compressing the medial rectus muscle was seen in a coronal paranasal sinus CT.

Case 3

A 43 years old male complained of a swelling under his right eyebrow 2.5 months ago, was admitted to an ophthalmologist, and then referred to a neurosurgeon. Brain magnetic resonance imaging (MRI) showed a low-density, homogeneous mass in the right frontal sinus that had eroded through the posterior wall

of the frontal sinus and formed a large extension into the anterior cranial fossa (Figure 3). The lesion had severely compressed the right frontal lobe. The patient was referred to our clinic by the neurosurgeon. An axial and coronal paranasal CT showed a frontal mucocele. Intranasal endoscopic examination showed no evidence of paranasal infection. The patient underwent frontal sinus surgery with osteoplastic flap. The mucocele was drained, the defect on the posterior wall of the frontal sinus was repaired with lioflized dura, and the frontal sinus was obliterated with abdominal fat. The patient was followed for 2 years, with no relapse or complications.

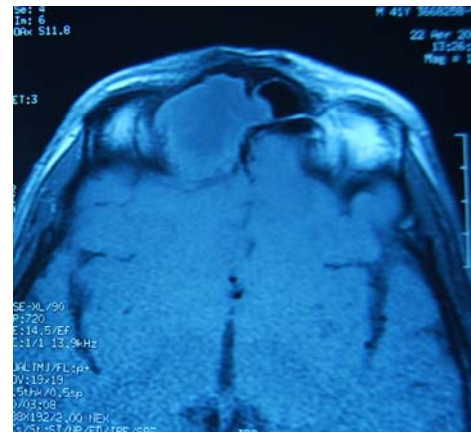


Figure 3. Preoperative MRI showing frontal sinus mucocele.

Case 4

A 41 years old female was admitted to our outpatient clinic with a resistant headache localised on the left supraorbital region. She had no history of trauma or surgery. A nasoendoscopic examination found a mucopurulent secretion in the left nasal cavity. The paranasal sinus CT proved a left frontal opacity that was thought to be a mucocele (Figure 4). The patient underwent frontal sinus surgery with osteoplastic flap and frontal obliteration with fat. The procedure was accomplished successfully without complications. Nearly one year since the procedure, the patient is without recurrence or complication.

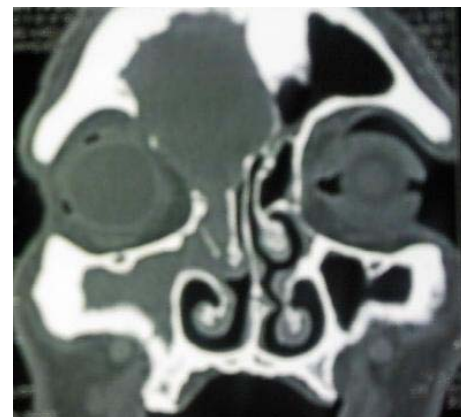

Figure 4. Left frontal opacity in the left frontal sinus that was thought to be a mucocele was seen.

Case 5

A 13 years old boy was admitted to our clinic with a one-year history of bilateral nasal obstruction, especially on the left side. He had no smell disorder and denied any visual symptoms. He had no history of major maxillofacial trauma or nasal surgery. On his nasoendoscopic examination, bilateral septal swelling that was more prominent on the left side and minimal adenoid hypertrophy was detected. A CT revealed a large midline septal mass without intracranial extension (Figure 5). The patient underwent endoscopic drainage and total excision of the septal mucocele and endoscopic mini-septoplasty under general anaesthesia. There were no remnants of cartilage or bony septum identified within the septal mucocele. The diagnosis of a mucocele was confirmed histologically. He was symptom free over the next 10 months and there were no evidence of recurrence.

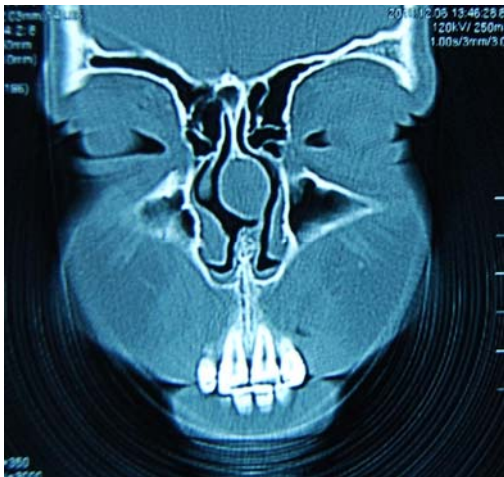

Figure 5. The midline mass localised in the nasal septum.

DISCUSSION

Paranasal sinus mucoceles are cystic lesions filled with mucous or mucopurulent material that overfill the sinus. They are locally expansile and can cause bone destruction. The encapsulated lesion covered with the pseudostratified columnar respiratory epithelium is surrounded with mucoperiosteum of the affected sinus. Mucoceles can be divided into two categories primary and secondary. In primary mucoceles, inflammatory blockage of mucus drainage, secretory duct obstruction, cystic dilation of mucosal glands, and cystic degeneration of polyps are believed to be the possible underlying mechanisms (5). Secondary mucoceles can result from trauma, chronic sinusitis, neoplasm, post-sinus surgery complications, or allergic reactions.

The frontal sinus is the most common site of the paranasal sinus mucoceles (60 per cent), followed by the ethmoid sinuses (30 per cent). Only 10 per cent are found in the maxillary sinuses and are rarely localized in the sphenoid sinus. The relevant literature reported some less common and unusual sites for mucoceles.

Arrue et al. described mucoceles of the pterygomaxillary space, orbital floor, root of the nose and middle turbinate in a concha bullosa (1).

Middle turbinate mucoceles are rarely reported. Concha bullosa is a common variant of nasal anatomy found in 34 percent of patients having CT for the evaluation of symptomatic sinus disease (3). Concha bullosa is an important structure composing a cavity that can result in mucocele/pyocele, blocking the ethmoid infundibulum and leading to chronic ethmoidal and antral disease. The scar tissues forming after surgery or local inflammatory oedema because of allergic rhinitis can obstruct the ostium of concha bullosa that connects the bullosa to the frontal recess and reveal a mucocele. However, the etiology of mucocele of our case is not clear.

Mucocele of the nasal septum is extremely rare. Gall and Witterick (4) reported only one case of mucocele of the nasal septum that occurred as a result of patient's previous nasal surgery. To our knowledge, our patient is the second case of mucocele of the nasal septum and the first case in a child. Furthermore, in our case, there were no predisposing factors. Septal mucoceles occur as a midline septal mass leading to nasal obstruction. The differential diagnosis of a mass in this region should consider a dermoid cyst, encephalocele, meningocele or intraseptal abscess.

The diagnosis of the paranasal sinus mucocele is based on the findings of stories, physical examinations, nasal endoscopy and radiological techniques. The manifestation of paranasal sinus mucocele depends on the vital structure involved and can be classified with rhinological, ophthalmologic, and neurologic symptoms and signs (6). Mucoceles arising within the frontal and anterior ethmoid sinuses commonly produce frontal headache, proptosis, periorbital swelling and reduced ocular mobility. On the other hand, mucoceles involving the posterior ethmoid and sphenoid sinuses have more subtle symptoms and present with visual disturbance, generalized headache with occipital and vertex pain, globe displacement, and diplopia (7). A mucocele can become infected and form a mucopyocele, with risk of infectious complications including meningitis, orbital cellulitis, and osteomyelitis. Radiological imaging techniques and nasoendoscopy are very useful in the differential diagnosis and management of the disease. The CT scan provides the surgeon with important information about the local bony anatomy that can be used in pre-operative planning. Paranasal sinus mucoceles can be differentiated from paranasal sinus tumors, soft tissue, and dural inflammation visible on MRI (8).

The treatment of the mucocele is surgery. The main principle is opening the mucocele and creating a way for drainage. The marsupialization and drainage of the cyst is believed to be the mainstay of treatment and the endoscopic approach is the most successful tool in carrying out this type of surgical management. The

widest range of mucoceles treated exclusively with an endoscopic approach corresponds to Har-El (9), with 103 patients and an average follow-up of 4.6 years, in which only one relapse is noted. Moreover, in the series of Khong et al (10) 27 cases that include mucoceles with orbital affectation treated endoscopically a recurrence rate of 8.3 per cent is registered.

A review by Conboy and Jones (7) reported that some conditions are not suitable for endoscopic surgery alone, including a laterally placed frontal mucocele, hypertrophic bone occluding the area of the frontonasal recess, and a mucocele arising secondarily from a malignancy. Traditionally, non-endoscopic treatment of frontoethmoid mucoceles has involved trephination procedures or osteoplastic flap with mucosal extirpation and fat obliteration. Also endoscopic techniques including marsupialization and modified endoscopic Lothrop procedure have been used successfully to reduce both complicated frontal mucoceles and mucoceles of other paranasal sinuses. Khong et al (11) successfully used the modified endoscopic Lothrop procedure in treating 21 patients with frontal sinus mucoce-

les with a mean follow-up time of 16 months. All mucocele openings were initially patent; however, five of the 21 required additional surgery later, and four had minor complications that included epistaxis and adhesions. Meetze et al. (12) published a retrospective review of six patients with frontal sinus complications who had undergone previous frontal craniotomies. In one of our cases there was frontal lobe compression, but the patient was treated successfully without any complication. In all our cases, although open surgical procedures were also used, an endoscopic approach was the first choice of treatment.

In conclusion, mucoceles are common, benign, expansile cyst-like lesions affecting the paranasal sinuses. The majority occur in the fronto-ethmoid sinuses. Rarely, they have been reported in uncommon locations of the facial skeleton. We report five cases of mucoceles in four different locations, including two uncommon sites, treated with different surgical techniques.

REFERENCES

1. Thio D, Phelps PD, Bath AP. Maxillary sinus mucocele presenting as late complication of a maxillary advancement procedure. *J Laryngol Otol* 2003; 117: 402-3.
2. Arrue P, Kany MT, Serrano E, Lacroix F, Percodani J, Yardeni E, Pessey JJ, Manelfe C. Mucoceles of the paranasal sinuses: uncommon location. *J Laryngol Otol* 1998; 112: 840-4.
3. Harrison DFN, Lund VJ. Conditions Simulating Neoplasia. Tumors of the Upper Jaw; ch4. London: Churchill Livingstone; 54-62.
4. Gall R, Witterick I. Mucocele of the nasal septum. *J Otolaryngol* 2002; 31: 246-7.
5. Fu CH, Chang KP, Lee TJ. The difference in anatomical and invasive characteristics between primary and secondary paranasal sinus mucoceles. *Otolaryngol Head Neck Surg* 2007; 136: 621-5.
6. Lee TJ, Li SP, Fu CH, Huang CC, Chang PH, Chen YW, Chen CW. Extensive paranasal sinus mucoceles: a 15-year review of 82 cases. *Am J Otolaryngol* 2009; 30: 234-8.
7. Conboy PJ, Jones NS. The place of endoscopic sinus surgery in the treatment of paranasal sinus mucoceles. *Clin Otolaryngol Allied Sci* 2003; 28: 207-10.
8. Lloyd G, Lund VJ, Savy L, Howard D. Optimum imaging for mucoceles. *J Laryngol Otol* 2000; 114: 233-6.
9. Har-El G. Endoscopic management of 108 sinus mucoceles. *Laryngoscope* 2001; 111: 2131-4.
10. Khong JJ, Malhotra R, Wormald PJ, Selva D. Endoscopic sinus surgery for paranasal sinus mucocele with orbital involvement. *Eye (Lond)* 2004; 18: 877-81.
11. Khong JJ, Malhorta R, Selva D, Wormald PJ. Efficacy of endoscopic sinus surgery for paranasal sinus mucocele including modified endoscopic Lothrop procedure for frontal sinus mucocele. *J Laryngol Otol* 2004; 118: 352-6.
12. Meetze K, Palmer JN, Schlosser RJ. Frontal sinus complications after frontal craniotomy. *Laryngoscope* 2004; 114: 945-8.

Gönderilme Tarihi: 21.03.2012